

Central Neurocytoma in the Fourth Ventricle: Case Report and Literature Review

Jiangwei Ding

Ningxia Medical University

Yang Dong

Zhengzhou University First Affiliated Hospital

Lei Wang

Ningxia Medical University

Baorui Guo

Ningxia Medical University

Xinxiao Li

Ningxia Medical University

Lifei Xiao

Ningxia Medical University

Shucui Jiang

Ningxia Medical University

Changliang Zhu

Ningxia Medical University

Feng Wang

Zhejiang University School of Medicine

Tao Sun (✉ suntao_nxmu@163.com)

Zhejiang University School of Medicine

Case report

Keywords: Central neurocytoma, fourth ventricle, mixed neuronal-glioma tumours, Case report, Literature review

Posted Date: May 17th, 2021

DOI: <https://doi.org/10.21203/rs.3.rs-472481/v1>

License: © ⓘ This work is licensed under a Creative Commons Attribution 4.0 International License.

[Read Full License](#)

Abstract

Background: Central neurocytoma is a rare primary intracranial tumour that usually occurs in young people. Central neurocytoma is more common in the lateral ventricle, but it is rare in the fourth ventricle. Herein, we report a case of central neurocytoma in the fourth ventricle. To improve our understanding, diagnosis, and treatment of this disease, we reviewed the literature to analyse the age, gender, clinical manifestations, imaging characteristics, and surgical prognosis of CNC in the fourth ventricle.

Case presentation: A 44-year-old Chinese woman presented with headache and dizziness for 8 years, walking instability for 2 years, and aggravation for 1 month. MRI revealed a 3.0 cm × 3.6 cm × 3.4 cm lesion located in the fourth ventricle. The tumour was completely resected. Pathological results were consistent with central neurocytoma. The patient could not walk or speak fluently during post-operative period, and no recurrence was found during the seventh month of follow-up.

Conclusions: Central neurocytoma in the fourth ventricle is a rare intracranial tumour that is difficult to diagnose preoperatively. However, it can be considered when cystic and solid lesions are present in the fourth ventricle, especially when the morphology is like a soap bubble. Surgery is the main treatment for CNC. Adjuvant radiotherapy can be considered for partial or subtotal resection cases, and the prognosis is good. No recurrence of central neurocytoma in the fourth ventricle has been reported thus far.

Background

Central neurocytoma (CNC) is a rare primary intracranial tumour that was first identified and named by Hassoun in 1982 [1]. It is common among young people, accounting for approximately 0.25–0.5% of all intracranial tumours [2–5]. The majority of CNS cases are located in the lateral ventricle and can straddle the bilateral ventricle and also burst into the third ventricle. However, primary CNS tumours in the fourth ventricle are extremely rare, and only 15 cases (including the present case) have been reported thus far [6–18].

Case Presentation

A 44-year-old female patient was admitted to our hospital with symptoms of headache and dizziness for 8 years, walking instability for 2 years, and aggravation for 1 month. Neurophysical examination demonstrated gait instability and Romberg signs (+). She had no remarkable past medical history. Magnetic resonance imaging (MRI) brain scan revealed a lesion in the fourth ventricle, mixed hypointense on T1 (Fig. 1A), and mixed hyperintense on T2 (Fig. 1B) with flair images slightly hyperintense (Fig. 1C). The lesions showed partial diffusion limitation and slightly high signal intensity of DWI high b-value (Fig. 1D). Supratentorial ventricle was enlarged (Fig. 1E), cerebellar and brainstem were compressed, and cerebellar tonsils were slightly downward, about 2 mm above the level of foramen magnum. Postgadolinium scan showed a mild progressive and inhomogeneous enhancement mass 3.0 cm × 3.6 cm × 3.4 cm in size (Figs. 1F–1H). Preoperative diagnosis was 1) fourth ventricle ependymoma, 2)

supratentorial hydrocephalus with interstitial cerebral oedema, and 3) mild inferior hernia of cerebellar tonsils.

Posterior occipital median approach was performed. After conventional craniotomy, the dura tension was high. The dura was cut and pulled to both sides. The cisterna magna was opened first to release part of the cerebrospinal fluid to reduce intracranial pressure. The inferior cerebellar vermis was then cut, and the left and right cerebellar hemispheres were pulled to both sides to expose and explore the fourth ventricle. The lesion was located and filled in the fourth ventricle. The mass was irregular in shape and rich in blood supply. The tumour was separated from the base of the fourth ventricle by a layer of arachnoid membrane. Under the microscope, the tumour was segmented and completely removed. The tumour was grey to grey red and soft. Postoperative pathology showed dense proliferation of tumour cells, which were arranged like solid sheets or a girder cord. The cells were moderately heteromorphic, and scattered calcification was observed. In a few areas, tumour cells were seen around the blood vessels, and some of the cytoplasm of the tumour cells was empty and bright, similar to oligodendritic cells (Fig. 2). Immunohistochemical examination indicated that the tumour cells expressed synaptophysin, nestin, MAP2, and Calretinin, but were negative for glial fibrillary acidic protein and neurofilament. The Ki-67 proliferation index was about 10% (not shown). The pathological results were consistent with CNC.

Postoperative MRI (Figs. 3A–3D) was conducted for 7 months and showed that the tumour was completely resected without recurrence. Follow up via telephone 3 years after the operation showed that the patient could still not walk nor speak fluently and required constant care and attention.

Discussion And Conclusions

Since Warmuth-Metz et al. first reported CNC in 1999 [6], only 15 cases (excluding one case of cerebellar liponeurocytoma in the fourth ventricle [19]), have been reported [6–18]. CNC cases were slightly more common in females than in males (female:male = 9:6) and more common in adults than in children (adult: children = 12:3). The average age was 38 years (range: 7–70), and median age was 34 years. The clinical manifestations of CNC in the fourth ventricle are not specific. Similar to other tumours in the fourth ventricle, the clinical manifestations of CNC in the fourth ventricle are mainly related to the size of the tumour and its adjacent areas. The main clinical manifestations of fourth ventricle tumours are intracranial hypertension caused by obstructive hydrocephalus, such as headache, dizziness, malignant vomiting, blurred vision, and standing instability and ataxia caused by compression of the surrounding tissues, such as brain stem and cerebellum. In 15 CNC cases reported in the literature thus far (**Table 1**), the main clinical manifestations are still symptoms of intracranial hypertension, such as headache, nausea and vomiting, as well as papilledema-related symptoms (14/15, 93.3%), including headache in 10 cases (10/15, 66.7%), nausea and vomiting in 9 cases (9/15, 60.0%), diplopia or blurred vision in 2 cases (2/15, 13.3%), ataxia or gait instability in 4 cases (4/15, 26.7%), lower limb weakness in 2 cases (2/15, 13.3%), and altered taste, tinnitus, and vertigo in one case respectively. Obstructive hydrocephalus is the main clinical manifestation of intraventricular neurocytoma. In the 15 cases of CNC in the fourth ventricle, hydrocephalus occurred in 10 cases. The appearance of acute obstructive hydrocephalus can

suddenly aggravate the patient's condition, even cerebral hernia, which is one of the indications of acute extraventricular drainage. In addition, when the tumour bleeds, it may suddenly aggravate the patient's symptoms.

MRI is the first choice for the diagnosis of CNS tumours. Our previous study [20] showed that CNS tumours in the lateral ventricle generally present mild low-intensity to equal-intensity signals on T1WI, whereas T2WI presents equal-intensity to high intensity signals. In both T1 and T2 weighted images, a low density may indicate haemorrhage, cysts, or calcification. After injection of an enhancer, the MRI showed notable enhancement of heterogeneity in the solid portion of the tumour. The tumours were mostly cystic and solid. Is there a similar imaging pattern in CNS tumours of the four ventricles? Through comparative analysis of 15 cases of CNS tumours in the four ventricles, we found that the imaging manifestations of CNS tumours in the four ventricles were similar to those in the lateral ventricle, and most of them were mainly cystic and solid, with calcification, haemorrhage, and cystic degeneration [6, 7, 10, 14]. The radiographic findings of our case were quite special. Obvious cystic and solid lesions were present in the four ventricles. The soap bubble appearance on T2WI (Fig. 1B) was similar to that of CNC in the lateral ventricle (Figs. 4A–4D) [20]. Owing to the rarity of CNC in the fourth ventricle, accurate imaging diagnosis of this disease is extremely difficult, and it should be differentiated from other diseases, including ependymoma, medulloblastoma, ependymoma, choroid plexus papilloma, and rosette-forming glioneuronal tumour [17, 21].

Postoperative pathology is helpful for the diagnosis of CNC. Under the microscope, the tumour cells were all small round cells, and some of them had perikaryotic halo or transparent cytoplasm. Moreover, island cell-free areas were present. Syn is a transmembrane glycoprotein that exists in the presynaptic vesicle of neurons. Syn positive expression is an important indicator of nerve cells and tumours, and it is one of the main molecular markers of CNC. NSE is a glycolytic enzyme located in the cytoplasm of neurons and can also be found in CNC, but it can exist in non-neural tumours and lacks relative neural specificity. In addition, neuronal nucleus (NeuN) and epithelial membrane antigen (EMA) are helpful for the diagnosis and differentiation of CNC. Glial fibrillary acidic protein (GFAP) is commonly found in glial cell tumours. GFAP is positive in some CNC, suggesting that tumour cells may originate from progenitor cells or stem cells with bi-directional differentiation in the paraventricular region. When Syn is uncertain, electron microscopy can be performed, but it is not the first choice for routine diagnosis. The Ki-67 marker index has been demonstrated to be the most important marker of potentially malignant behaviour in CNC. Söylemezoglu et al. [22] argued that CNC is atypical if the Ki-67 marker index is greater than or equal to 2%. Among the 15 CNC cases reported in the literature (among which 1 case did not provide immunohistochemical results), 12 cases were positive for Syn, 6 for NSE, 4 for Neun, and 3 for GFAP, and the rest were positive for NF, EMA, S-100, Vimrntin, Bcl-2, Olig-2, MAP2, and Calretinin. The Ki67 index ranged from 1–30%. Unlike Söylemezoglu et al. [22], other researchers did not diagnose the disease as atypical central neuroblastoma although Ki-67 was greater than 2% in some of the 15 cases probably because the diagnosis of atypical central neuroblastoma not only requires Ki-67 greater than 2% but also is related to whether the tumour is accompanied by microvascular proliferation, mitosis, and necrosis. It is characterized by elevated MIB labelling index (MIB-1 LI) more than 2% or 3% and/or accompanying

histological atypia, such as infiltrative margins, increased mitosis, pleomorphism, endovascular proliferation, and necrosis [23, 24].

Microsurgical resection is the preferred treatment for CNC, which can be adjuvant to radiotherapy. In the 15 CNC cases reported in the literature, only 12 (including the present report) provided complete treatment details (Table 1). In these 12 cases, 9 (75%) patients received treatment by surgery alone, 3 (25%) received both surgery and radiation therapy, and no one was treated with chemotherapy. With regard to surgery type, GTR was performed in 8 (66.7%) cases. Subtotal resection was performed in 4 (33.3%) cases, and only 3 cases underwent surgery. No recurrent cases were reported in the 15 cases.

Treatment via gross total resection is the gold standard. Although total tumour resection can obtain good prognosis and can minimize the recurrence rate, it is difficult to perform for CNC cases located in fourth ventricle because they are likely to be closely tied to the brain stem, must not impinge tumour whole cutting, can take full or partial nephrectomy. CNC is sensitive to radiotherapy, but the advantages and disadvantages of radiotherapy should be weighed because of the low malignant degree of CNC [24–26]. Whether radiotherapy should be used in patients with total tumour resection remains controversial. Rades et al. [27] stated that adjuvant radiotherapy after total tumour resection does not improve local control and patient prognosis. At present, the following cases are considered to be radiotherapy [28, 29]: 1) gross tumour resection but Ki-67 > 2% or 3%, 2) tumour is pathologically atypical, and 3) unresectable, subtotal resection, and recurrent CNC. For patients with subtotal resection, radiotherapy can not only substantially reduce the recurrence rate of tumour but also reduce residual tissues. Currently, the recommended dose of radiotherapy is 54–60 Gy. If postoperative recurrence occurs, then surgery (or stereotactic radiotherapy) may still be the first choice. Schild et al. [25] reported a 5-year survival rate in 88% of patients receiving either fractionated radiotherapy or stereotactic radiosurgery after surgical resection and only 71% of patients without adjuvant radiotherapy. Rades et al. [27] reviewed 310 CNC cases retrospectively and found that partial resection combined with radiotherapy provided better local control compared with partial resection alone, although it did not improve overall survival. Warmut-Metz et al. [6] performed radiotherapy (50.4 Gy) on an incomplete resection of CNC in the fourth ventricle. They observed some regression of residual tumour tissues during follow up 4 months later. Cook et al. [8] performed radiotherapy on a patient with incomplete resection and disseminated spinal cord, and the residual tumour was remarkably improved and the disseminated spinal cord lesion disappeared. The evidence of chemotherapy for CNC is obviously inadequate relative to that of radiotherapy. Lee et al. [30] suggested that although chemotherapy cannot be used as a routine treatment for CNC, it can still be used as a remedial treatment. Temozolomide was also incorporated into the chemotherapy regimen of CNC. However, the chemotherapy of CNC still warrants further research and verification [31].

In conclusion, CNC in the fourth ventricle is a rare intracranial tumour that is difficult to diagnose preoperatively. However, it can be considered when cystic and solid lesions are present in the fourth ventricle, especially when the morphology is like a soap bubble. Surgery is the main treatment for CNC, and adjuvant radiotherapy can be considered for partial or subtotal resection cases with good prognosis. No recurrence of CNC of the fourth ventricle has been reported thus far.

Abbreviations

MRI, Magnetic resonance imaging; CNC, Central neurocytoma. F: Female; M: Male; NA: Not available; GTR: gross total resection; STR: Subtotal resection; RT: Radiotherapy; EVD: External ventricular drainage; VPS: Ventriculo-peritoneal shunt;

Pos: Positive; Neg: negative; Syn: Synaptophysin; NF: Neurofilament; GFAP: glial fibrillary acid protein; EMA: Epithelial membrane antigen; Vim: Vimentine; T1:T1WI;

T2:T2WI; M: Month(s).

Declarations

Acknowledgements

None.

Authors' contributions

All authors contributed to the study conception and design. The material preparation, data collection, and analysis were performed by Ding JW, Dong Y, Wang L, Guo BR, Li XX, Xiao LF, Jiang SC, Zhu CL, Wang F and Sun T. The first draft of the manuscript was written by Ding JW, and all authors commented on the previous versions of the manuscript. All authors read and approved the final manuscript.

Funding

This study was funded by the Ningxia Hui Autonomous Region "13th Five-Year Plan" Major Science and Technology Projects (2016BZ07) grant.

Availability of data and materials

All data generated or analyzed are included in this published article

Ethics approval and consent to participate

The study was approved by the ethics committee of the General Hospital of Ningxia Medical University. The patient gave consent to participate.

Consent for publication

Informed consent was obtained from all individual participants included in the study.

Competing interests

The authors declare that they have no competing interest.

Author details

*Correspondence: Tao Sun, suntao_nxmu@163.com

¹ Ningxia Key Laboratory of Cerebrocranial Disease, Ningxia Medical University, 1160 Shengli Street Xingqing District, Yinchuan, Ningxia 750001 China;

² Department of Neurosurgery, General Hospital of Ningxia Medical University, 804 Shengli Street Xingqing District Yinchuan, Ningxia 750001 China;

³ Department of Neurosurgery, The First Affiliated Hospital of Zhengzhou University, 1 Jianshe East Road Erqi District, Zhengzhou, Henan 450052 China;

⁴ Department of Neurosurgery, The First Affiliated Hospital Zhejiang University School of Medical, 1367 Wenyi West Road Yuhang District Hangzhou, Zhejiang 310011 China.

References

1. Hassoun J, Gambarelli D, Grisoli F, et al. Central neurocytoma. An electron-microscopic study of two cases. *Acta Neuropathol.* 1982;56:151–6.
2. Coca S, Moreno M, Martos JA, et al. Neurocytoma of spinal cord. *Acta Neuropathol.* 1994;87:537–40.
3. Figarella-Branger D, Soylemezoglu F, Kleihues P, et al. Central neurocytoma. In: Kleihues P, Cavenee WK, editors. *Pathology and genetics of tumors of the nervous system.* Lyon: IARC Press; 2000. pp. 107–9.
4. Hassoun J, Söylemezoglu F, Gambarelli D, et al. Central neurocytoma: a synopsis of clinical and histological features. *Brain Pathol.* 1993;3:297–306.
5. Kim DG, Chi JG, Park SH, et al. Intraventricular neurocytoma: clinicopathological analysis of seven cases. *J Neurosurg.* 1992;76:759–65.
6. Warmuth-Metz M, Klein R, Sörensen N, et al. Central neurocytoma of the fourth ventricle. Case report. *J Neurosurg.* 1999;91:506–9.
7. Hsu PW, Hsieh TC, Chang CN, et al. Fourth ventricle central neurocytoma: case report. *Neurosurgery.* 2002;50:1365–7.
8. Cook DJ, Christie Sean D, Macaulay Robert JB, et al. Fourth ventricular neurocytoma: case report and review of the literature. *Can J Neurol Sci.* 2004;31:558–64.
9. Cultrera F, Giuffrida M, Guiducci G, et al. Central neurocytoma of the fourth ventricle. Case history. *J Neurosurg Sci.* 2005;49:125–8.
10. Gallina P, Mouchaty H, Buccoliero AM, et al. Haemorrhagic central neurocytoma of the fourth ventricle. *Acta Neurochir (Wien).* 2005;147:1193–4.
11. Li Jian, Cao DR, Xing Z, et al. The fourth ventricle central neurocytoma: A case report. *Chin J Radiol.* 2009;43(12):1331–2.

12. Gao B, Liu FL, Lang ZQ, et al. Clinical and imaging features of central neurocytoma of the fourth ventricle. *Chin J Neurosurg*. 2011;27(8):841–4.
13. You C, Chai WM, Chen K, et al. MRI Features of Central Neurocytomas in the Fourth Ventricle (report of 2 cases and review of the literature). *Chinese Journal of CT MRI*. 2011;09(2):74–5.
14. De J, Roy S, Chopra S, et al. Atypical central neurocytoma of fourth ventricle with hemorrhagic complication during surgery in a child. *Clin Neurol Neurosurg*. 2012;114:182–4.
15. Zhang ZQ, Zhang JY, Duan HZ, et al. The fourth ventricle central neurocytoma: A case report. *Chin J Minim Invasive Neurosurg*. 2017;22(10):467–8.
16. Cao J, Zhang J. The fourth ventricle central neurocytoma: A case report. *Chin J Magn Reson Imaging*. 2017;8(6):462–4.
17. Richardson AM, Armstrong VL, Gernsback JE, et al. Central Neurocytoma: Rare Presentation in Fourth Ventricle and Review of Literature. *World Neurosurg*. 2019;123:357–61.
18. Tang MX, Li YG. The fourth ventricle central neurocytoma: A case report. *Chin J Magn Reson Imaging*. 2019;10(6):450–1.
19. Jouvét A, Lellouch-Tubiana A, Boddaert N, et al. Fourth ventricle neurocytoma with lipomatous and ependymal differentiation. *Acta Neuropathol*. 2005;109(3):346.
20. Ding JW, Zhou G, Ding DL, et al. Central neurocytoma: A clinicopathological analysis of 51 cases. *Chinese Journal of Practical Nervous Diseases*. 2018;21(19):2125–30.
21. Shih RY, Smirniotopoulos JG. Posterior fossa tumors in adult patients. *Neuroimaging Clin N Am*. 2016;26:493–510.
22. Söylemezoglu F, Scheithauer BW, Esteve J, et al. Atypical central neurocytoma. *J Neuropathol Exp Neurol*. 1997;56:551–6.
23. AbdelBari MM, Shebl AM, Toson EA, et al. Atypical Central Neurocytoma: An Investigation of Prognostic Factors. *World Neurosurg* 2020; undefined: undefined.
24. Vasiljevic A, Francois P, Loundou A, et al. Prognostic factors in central neurocytomas: a multicenter study of 71 cases. *Am J Surg Pathol*. 2012;36(2):220–7.
25. Schild SE, Scheithauer BW, Haddock MG, et al. Central neurocytomas *Cancer*. 1997;79:790–5.
26. Patil AS, Menon G, Easwer HV, et al. Extraventricular neurocytoma, a comprehensive review. *Acta Neurochir*. 2014;156(2):349–54.
27. Rades D, Fehlaue F. Treatment options for central neurocytoma. *Neurology*. 2002;59(8):1268–70.
28. Leenstra JL, Rodriguez FJ, Frechette CM, et al. Central neurocytoma: management recommendations based on a 35-year experience. *Int J Radiat Oncol Biol Phys*. 2007;67:1145–54.
29. Byun J, Hong SH, Yoon MJ, et al. Prognosis and treatment outcomes of central neurocytomas: clinical interrogation based on a single center experience *Journal of Neuro-Oncology* 2018:1–9.
30. Lee SJ, Bui TT, Jacky CC, et al. Central Neurocytoma: A Review of Clinical Management and Histopathologic Features. *Brain Tumor Research Treatment*. 2016;4(2):49–57.

31. Johnson MO, Kirkpatrick P, Patel MP, et al. The role of chemotherapy in the treatment of central neurocytoma. *CNS Oncol.* 2019;8:CNS41.

Tables

Due to technical limitations, table 1 is only available as a download in the Supplemental Files section.

Figures

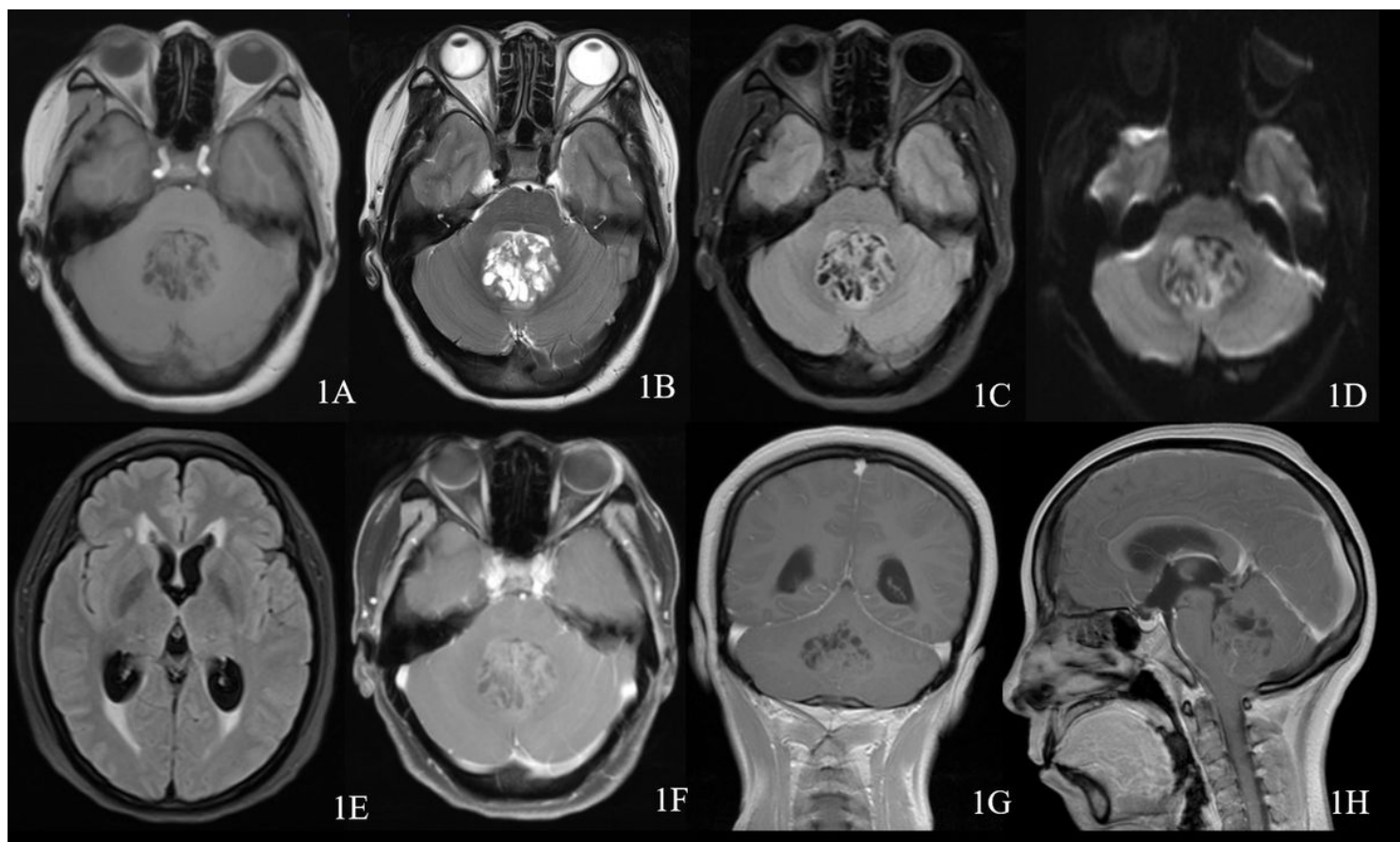


Figure 1

Preoperative examination. (A–E) The tumour was cystic and solid, and the lesion was like a soap bubble on T2WI. Axial T1WI mixed low signal, T2WI mixed high signal, blackwater image slightly higher signal, DWI high B value dispersion limited. (F–H) Postgadolinium scan showed a mild progressive and inheterogeneous enhancement mass.

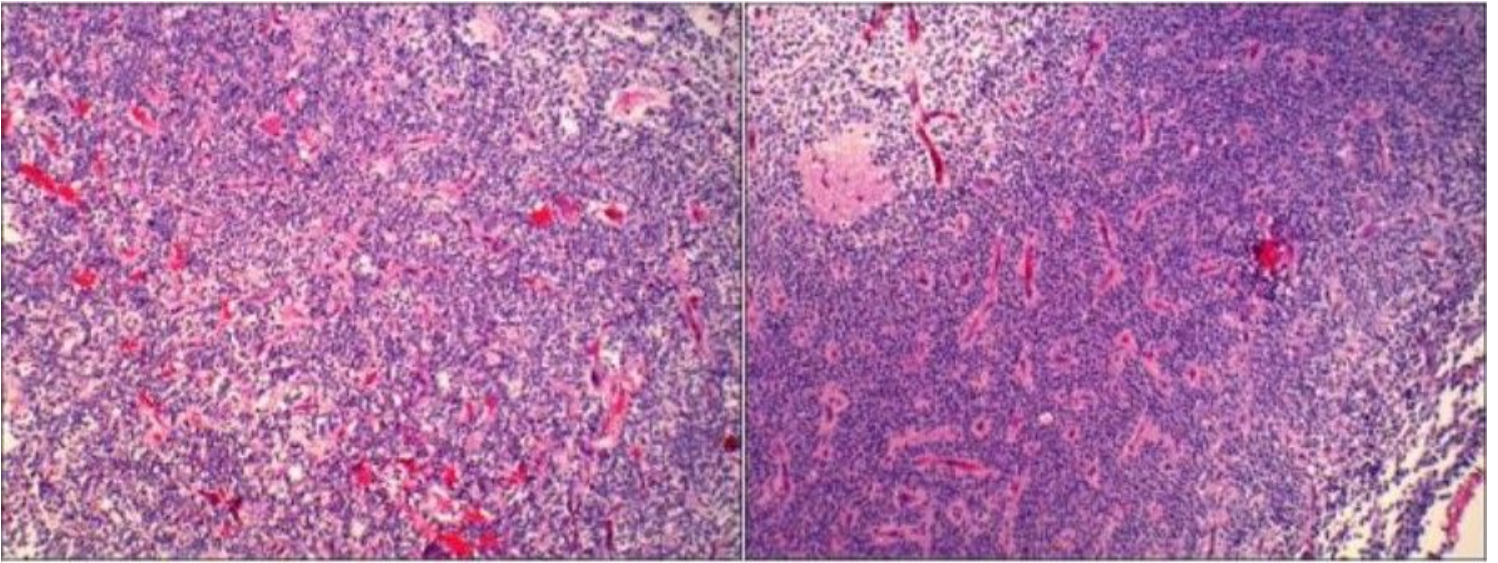


Figure 2

Postoperative pathology. Histopathology showed dense proliferation of tumour cells, which were arranged like solid sheets or a girder cord. The cells were moderately heteromorphic, and scattered calcification was observed. In a few areas, tumour cells were seen around the blood vessels, and some of the cytoplasm of the tumour cells was empty and bright, similar to oligodendritic cells.

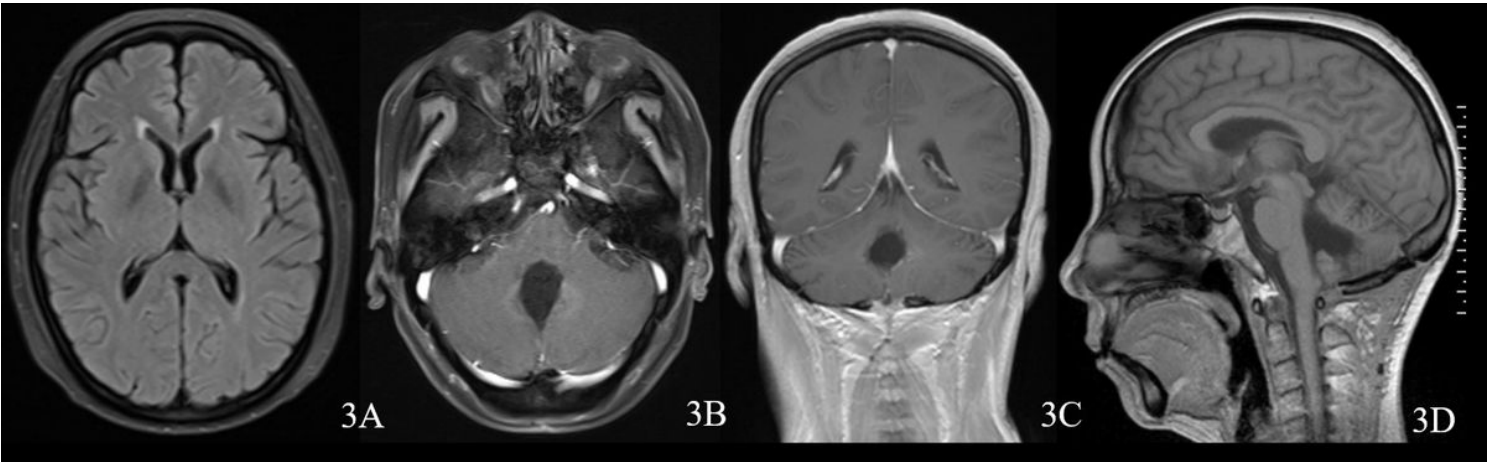


Figure 3

Postoperative images (7 months after surgery): hydrocephalus and oedema significantly improved and basically disappeared. No recurrence was observed after complete resection of the lesion.

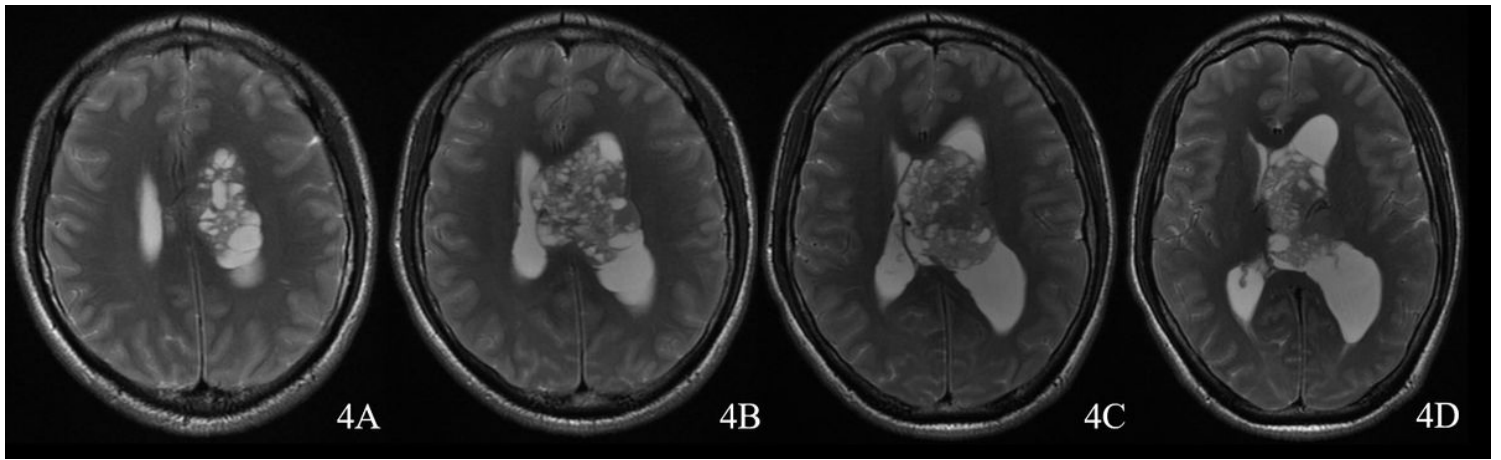


Figure 4

Imaging of a central neurocytoma in the lateral ventricle shows a soap-like cystic and solid lesion on T2WI.

Supplementary Files

This is a list of supplementary files associated with this preprint. Click to download.

- [Table.xls](#)