

Sarcoidosis As A Testicular Mass

David Schechter, M.D., Lawrence Paletz, M.D., Paul Lin, M.D., and James Keefe, M.D.

Sarcoidosis rarely involves the testicle. Seven cases detected clinically were described in a review in 1986,¹ and additional cases have been discovered on autopsy. Sarcoidosis involving the epididymis is a little more common, being found in somewhat less than 1 percent of all men with the disease.²

We report a case of testicular sarcoidosis diagnosed after orchiectomy in a previously healthy man.

Case Report

A 30-year-old black man came to the walk-in clinic complaining of a productive cough persisting for several weeks, mild fatigue, and an episode of low-grade fever. Concurrently, he reported noticing a lump in his testicle, which he discovered the previous week while showering. He denied dyspnea, night sweats, or weight loss. The patient had been previously healthy and was a monogamous heterosexual who denied any history of intravenous drug use.

The patient worked in the cargo department of an airline. He was born in the Northeast but had lived in southern California for several years. Medical, family, and occupational histories were otherwise unremarkable.

On physical examination, the patient's temperature was 36.9°C (98.4°F). Respiratory rate was 14/min and unlabored. His physical examination was notable for bibasilar rales. There were no wheezes or rhonchi. Findings on cardiac, skin, and neurologic examinations were entirely unremarkable. No lymphadenopathy was noted. There was, however, a 1.5-cm firm, fixed, nontender lesion at the upper pole of the left testicle. The epididymis was nontender and free of induration.

A chest radiograph showed bilateral diffuse interstitial infiltrates without perihilar adenopathy. His white count was $4.0 \times 10^9/L$ (normal $[N] = 4.8-10.8 \times 10^9/L$) ($4000/mm^3$, $N = 4800-10,800/mm^3$) with a normal differential.³ Mild anemia was noted; his hemoglobin was 132 g/L (13.2 g/dL), hematocrit 0.40 (39.8 percent), and mean corpuscular volume 79.8 fL ($79.8 \mu m^3$). Platelet count was normal. A test for tuberculosis was nonreactive.

A diagnosis of atypical pneumonia was entertained, and the patient was prescribed erythromycin. He was advised that upon his scheduled follow-up visit in 4 days, further work-up of his testicular mass would begin.

At his return appointment his cough was less productive. Chest radiography and physical findings were unchanged. Cold agglutinins, *Legionella* titers, and a search for human immunodeficiency virus by enzyme-linked immunosorbent assay were negative. An ultrasonic scan of the testicles was ordered, and the sonogram revealed a hypoechoic density in the left testicle that suggested a neoplasm. Two 5-mm satellite lesions were also noted.

Given the likelihood of testicular cancer, a urologist was consulted, and the following results were obtained: α -fetoprotein (AFP) levels were normal at 3.4 $\mu g/L$ (3.4 ng/dL), quantitative human chorionic gonadotropin (β -HCG) was negative at "less than 5" IU/L (mIU/mL). Carcinoembryonic antigen was 4 g/L ($N = 0.0-5$ g/L) (4 mg/mL, $N = 0.0-5$ mg/mL). Urinalysis was normal. A computed tomographic scan of the abdomen showed moderate splenomegaly.

Preoperatively, a pulmonary specialist was consulted. Arterial blood gases revealed a pH of 7.4, pO_2 of 11.2 kPa (84 mmHg), pCO_2 of 5.4 kPa (40 mmHg), and a 96 percent saturation on room air. Spirometry testing of resting pulmonary function was normal. Total lung capacity, however, was 73 percent of predicted levels, and residual volume was only 28 percent. Diffusion capacity was within normal limits. The chemistry panel was remarkable only for elevations of globulin at 49 g/L ($N = 20-35$ g/L)

Submitted, revised, 18 March 1992.

From the Department of Family Medicine, Centinela Hospital, Inglewood, CA; the University of Southern California — California Medical Center Family Practice Residency, Los Angeles; and the Departments of Surgery, Internal Medicine — Pulmonary Division, and Pathology, Centinela Hospital, Inglewood, CA. Address reprint requests to David Schechter, M.D., Family Practice Residency, California Medical Center — Los Angeles, 1338 S. Hope Street, Los Angeles, CA 90015.

(4.9 g/dL, N = 2–3.5 g/dL) and total protein at 91 g/L, N = 60–85 g/L) (9.1 g/dL, N = 6–8.5 g/dL). Erythrocyte sedimentation rate was 26 mm/h (Westergren, N = 0–10 mm/h).

A presumptive diagnosis of testicular malignancy was made, and the patient had a radical orchiectomy with insertion of prosthesis under spinal anesthesia. He tolerated the procedure well. Gross pathologic examination of the left testicle at the time of surgery showed a rubbery, well-circumscribed parenchymal mass 2 cm in diameter at its widest dimension. The microscopic examination of the large mass and the two satellite lesions seen on the sonogram demonstrated noncaseating granulomas consistent with sarcoidosis (Figure 1).

A subsequent gallium scan of the lungs demonstrated diffuse uptake consistent with active inflammatory changes. Angiotensin converting enzyme levels were elevated at 4000 nkat/L (N = 133–867 nkat/L) (240 nmol/mL/min, N = 8–52 nmol/mL/min). The patient was prescribed prednisone and has improved clinically with markedly diminished cough and fatigue. His pulmonary function tests have returned to normal.

Discussion

Sarcoidosis is a multisystem granulomatous disorder of unknown cause that most often affects young adults.² It is an uncommon disease, which in the United States afflicts blacks disproportionately. The ratio of blacks to whites

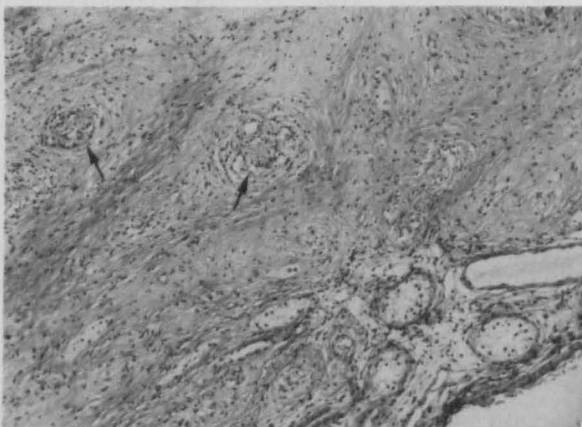


Figure 1. Photomicrograph of a representative section of testicular tissue, stained with hematoxylin-eosin. Clearly seen are multinucleated giant cells, noncaseating granulomas (arrows), and benign testicular parenchyma. (135 × magnification.)

could be as high as 17:1 and the female to male ratio is 2:1.²

Sarcoidosis can involve any organ; however, it is found in the lungs, peripheral lymph nodes, liver, skin, eye, or spleen most frequently. The typical presentation is asymptomatic perihilar lymphadenopathy discovered on a chest radiograph. The clinical course can vary from asymptomatic radiographic findings to severe multiple organ involvement with disability and rarely death. While rare, testicular involvement can occur.

Given the risk of missing a testicular malignancy at a potentially curable stage, many physicians would still opt for a radical orchiectomy in a unilateral testicular mass even in a patient known to have sarcoidosis. An alternative was presented by Turk, et al.,⁴ who advised an inguinal approach with an open biopsy. A vascular occlusion clamp was recommended to occlude the spermatic cord until results from frozen section could be made available.

Generally, prescribing corticosteroids to treat isolated testicular involvement is not advised.^{4,5} When preserving fertility is a strong consideration, however, this approach may be an option for the patient who has only one remaining testicle. A negative biopsy of a new lesion should first be obtained.

Sarcoidosis of the testicle is quite rare but should be considered in the differential diagnosis of a black man who does or does not report a history of sarcoidosis and who presents with a testicular mass.⁶ It is our intention to alert physicians to this connection so that management alternatives can be carefully considered.

References

1. Haas GP, Badalament R, Wonnell DM, Miles BJ. Testicular sarcoidosis: case report and review of the literature. *J Urol* 1986; 135:1254-6.
2. Zelitch SR, Israel HL. Sarcoidosis. *Am Fam Physician* 1988; 38:127-39.
3. Young DS. Implementation of SI units for clinical laboratory data. Style specifications and conversion tables. *Ann Intern Med* 1987; 106:114-29.
4. Turk CO, Schacht M, Ross L. Diagnosis and management of testicular sarcoidosis. *J Urol* 1986; 135:380-1.
5. Seaworth JF, Davis SJ, Donovan WN. Aggressive diagnostic approach indicated in testicular sarcoidosis. *Urology* 1983; 21:396-8.
6. Sieber PR, Duggan FE. Sarcoidosis and testicular tumors. *Urology* 1988; 31:140-1.